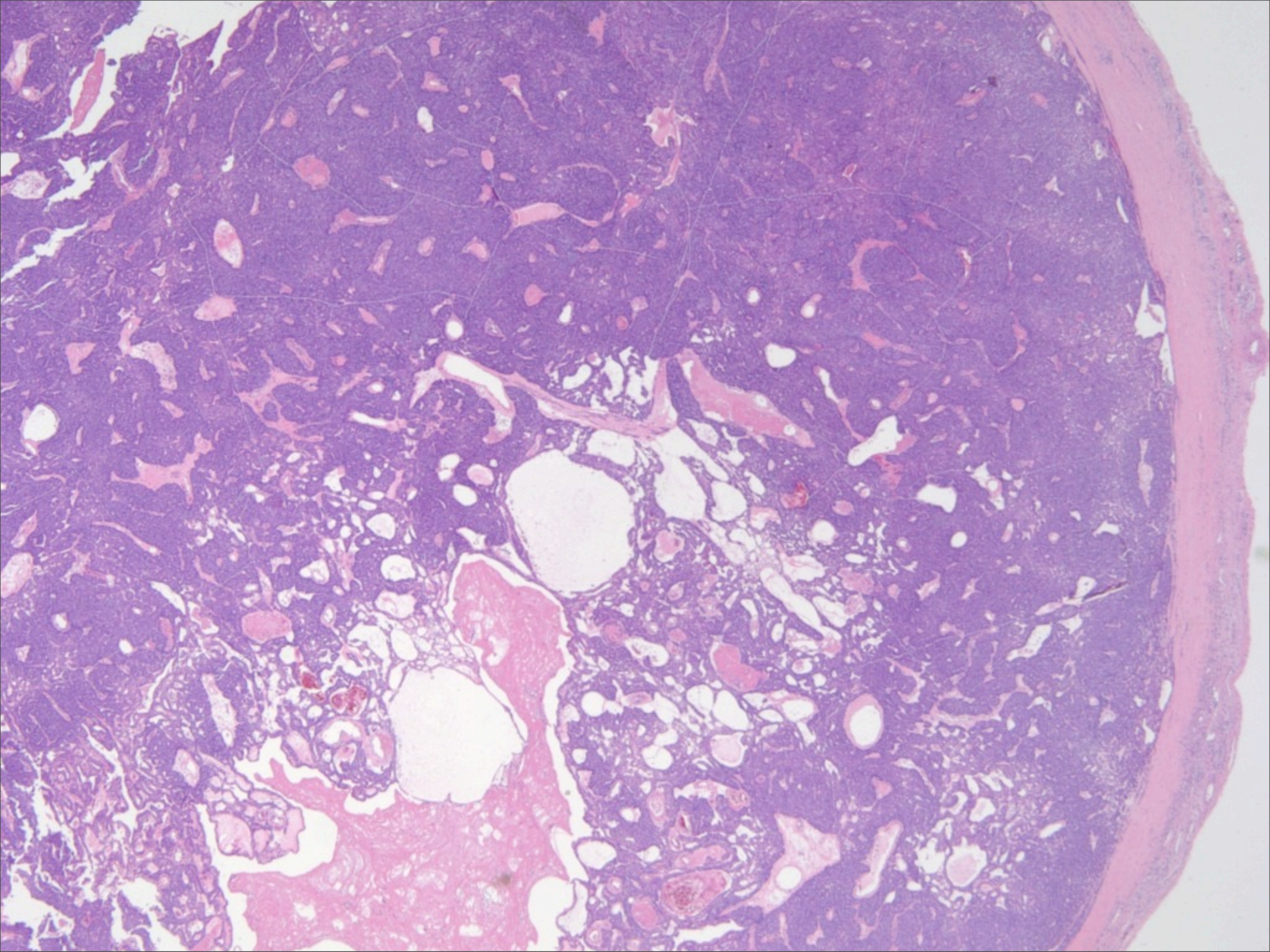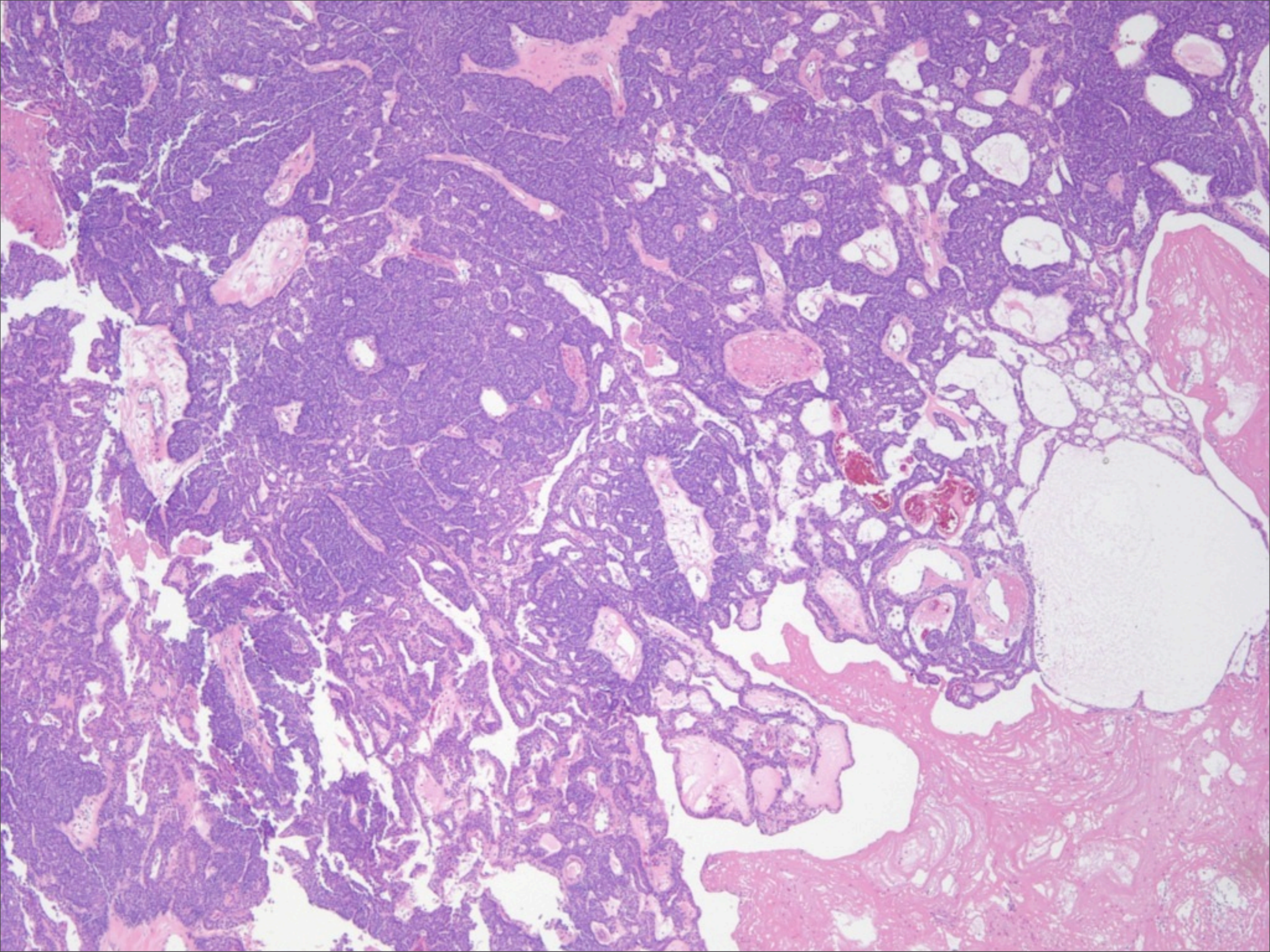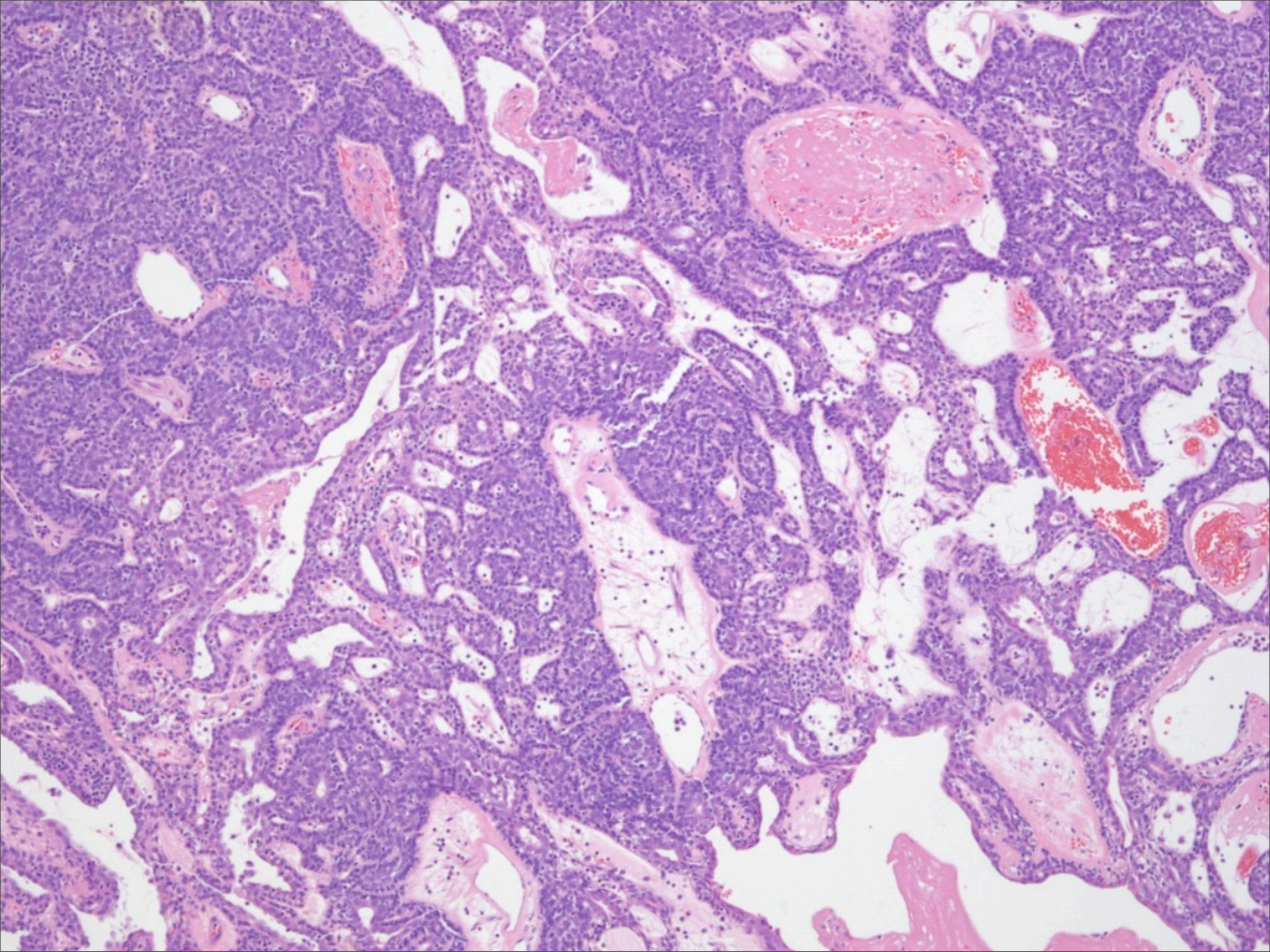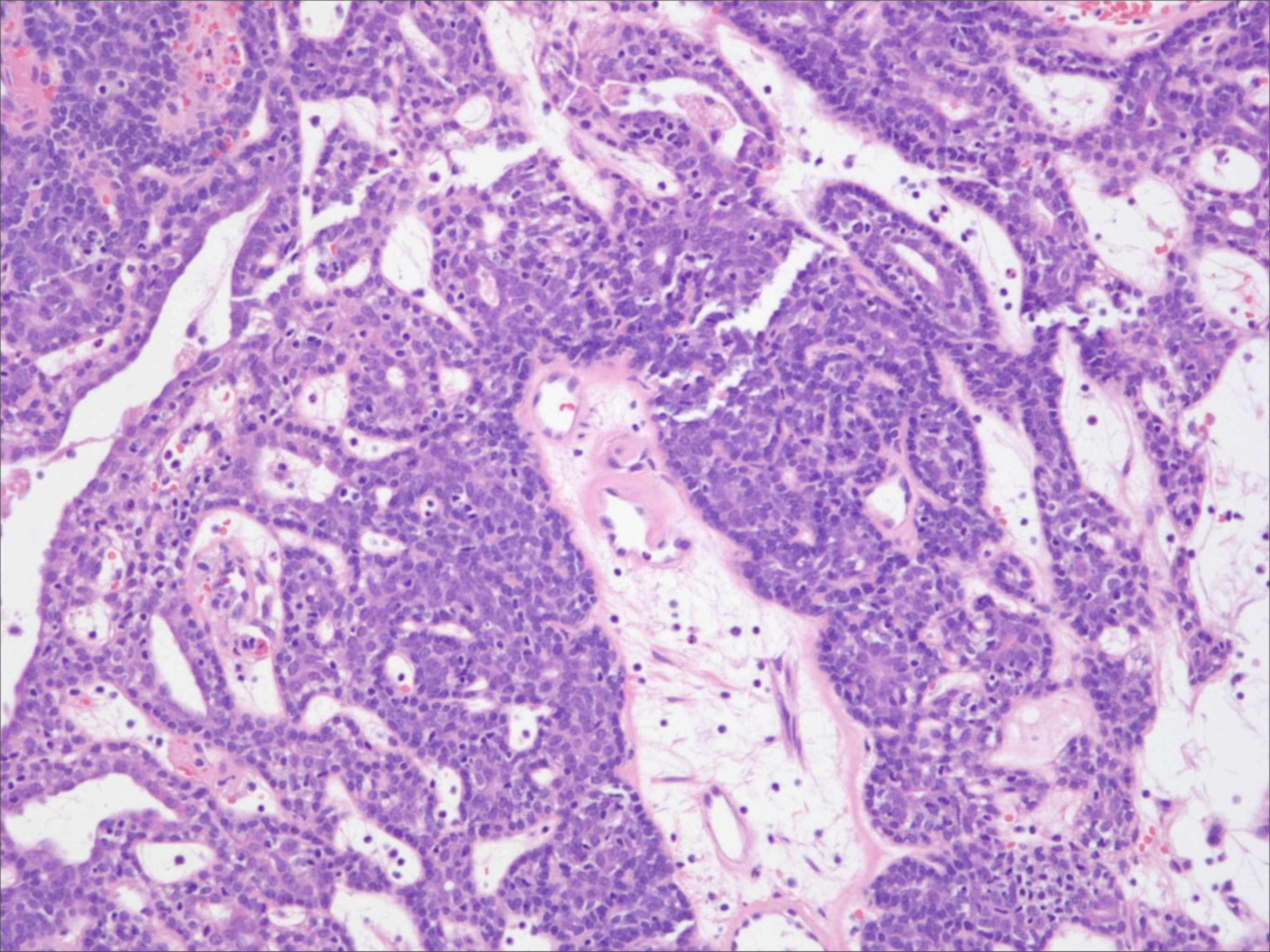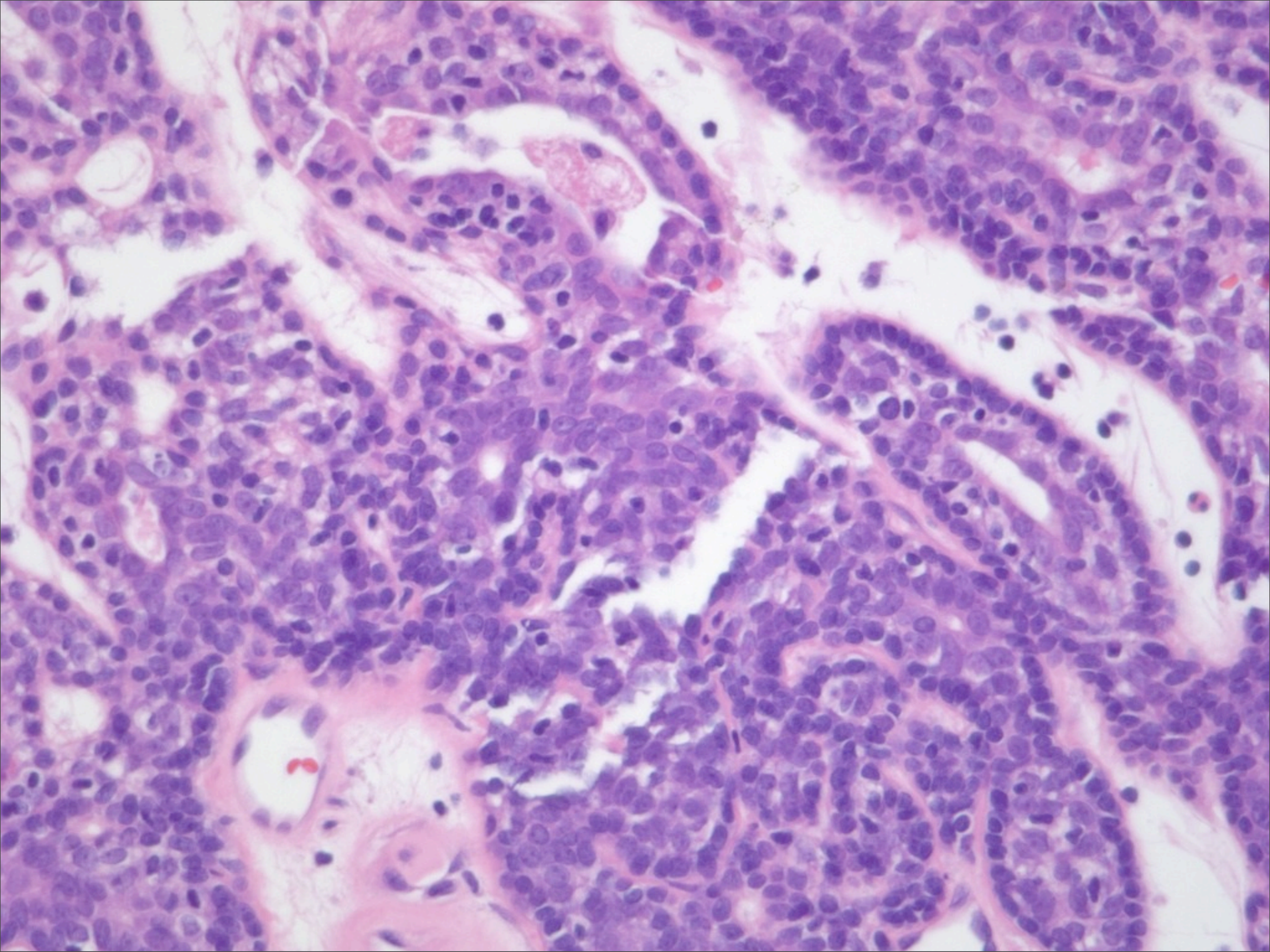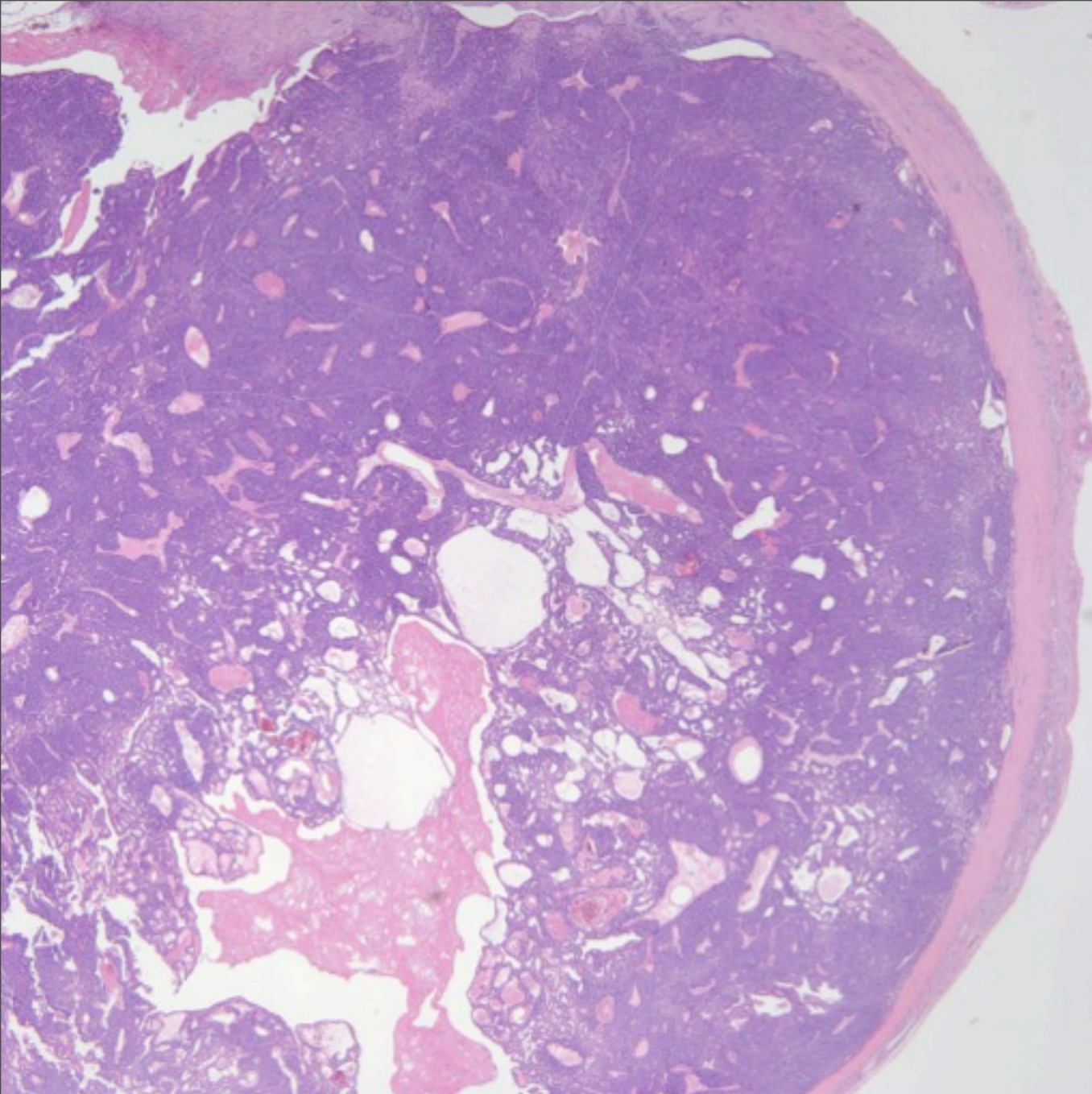


# Eccrine Spiradenoma



Circumscribed Dermal Tumor

Solid and Cystic

Hyalinized vessels

Basophilic cells with  
squamatization

Minimal cytologic atypia

DDX: Nodular BCC, Nodular hidradenoma,  
Trichoblastoma,